

CASE REPORT

Phialemonium curvatum infection after phacoemulsification: a case report

Roberto Freda¹, Melissa M. Dal Pizzol¹, João B. Fortes Filho²

¹Cornea and External Diseases Section, Department of Ophthalmology, Curso de Especialização em Oftalmologia do Hospital Banco de Olhos de Porto Alegre, Porto Alegre RS - Brazil

²Medical School, Federal University of Rio Grande do Sul and Hospital Banco de Olhos de Porto Alegre, Porto Alegre RS - Brazil

PURPOSE. *A case of Phialemonium curvatum wound corneal infection after phacoemulsification is reported.*

METHODS. *Case report.*

RESULTS. *The marked aggressiveness of this fungus is demonstrated by the absence of therapeutic response to both medical and surgical treatment.*

CONCLUSIONS. *The poor outcome resulted in evisceration of the affected eye.*

KEY WORDS. *Cornea, Corneal infection, Evisceration, Fungus, Phialemonium curvatum, Wound infection*

Accepted: April 23, 2011

INTRODUCTION

Phialemonium species are considered a dematiaceous or melanized fungus. They are saprobes, and were distributed widely in the environment being isolated from soil, water, air, and sewage. There are few reports of human diseases caused by *Phialemonium* species, which are almost exclusively in immunocompromised patients (1) and only 2 cases of intraocular involvement (2, 3). We report the first case of corneal infection due to *Phialemonium curvatum* after phacoemulsification.

Case report

An 84-year-old man presented with a 1-month history of prior uneventful cataract surgery. Eighteen days after the procedure, the patient complained of red eye, photophobia, ocular pain, and loss of vision in the right eye. At presentation, the best-corrected visual acuity was counting fingers at 2 meters. There was slight lid edema, intense conjunctival and limbal vascular injection, and a purulent discharge. There was a dense wound corneal infiltrate (Fig. 1) extending 5 mm inferiorly on the cornea and topical for-

tified vancomycin and tobramycin every hour regimen was immediately started. The anterior chamber was formed, but the iris was tamponading the corneal defect. A small hypopyon and a mild anterior chamber reaction were observed. The patient denied any trauma, systemic disease, immunosuppression, or use of contact lens.

Corneal scraping was performed in the center of the abscess, for bacteriologic and mycologic analysis. Scrapings were inoculated onto blood agar, brain-heart infusion, and Sabouraud agar. Silver methenamine staining demonstrated septated hyaline fungal hyphae. The patient was started on intense topical therapy with amphotericin B 0.15% and natamycin 5% every hour and oral ketoconazole 200 mg every 12 hours. Microbiologic studies confirmed a fungus growing in culture and DNA sequencing identified *P curvatum* (DNA sequencing with 3130 Genetic Analyzer, Applied Biosystems).

The patient was examined every day. As the corneal condition seemed to worsen every day, with extension of the abscess and impending perforation, a tectonic and therapeutic corneal keratoplasty was performed (Fig. 2). The patient was discharged receiving topical and oral antifungal treatment. Twenty days later, posterior segment ultrasono-

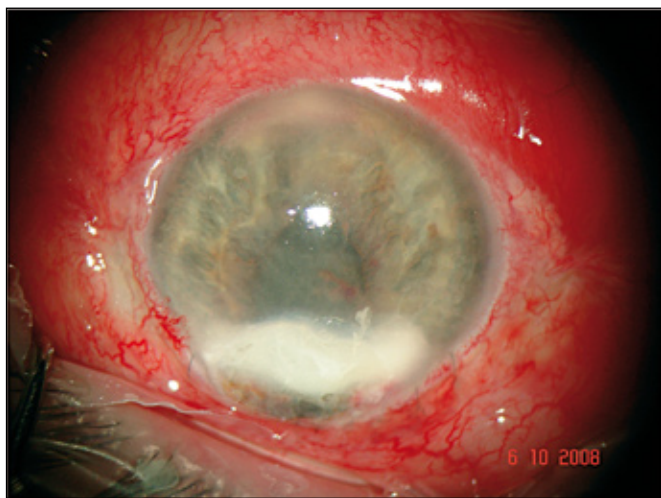


Fig. 1 - The patient at presentation with a dense wound corneal infiltrate.

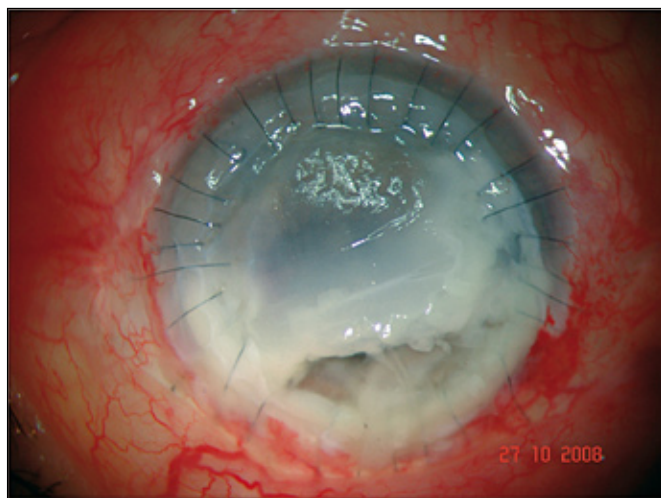


Fig. 2 - The recurrent corneal melting after tectonic keratoplasty.

graphy revealed an intense vitreous organization, choroidal thickening, but no retinal detachment. Intravitreal injection of amphotericin B and anterior chamber washout with the same drug were immediately performed. Nevertheless, a recurrent dense infiltrate of the cornea continued to enlarge and 2 days later the cornea was in an advanced melting process. Due to the dire condition of the eye, surgical management was indicated. The cornea was in an advanced melting process and the necrotic area of the cornea was excised, leaving only a small portion of inferior unaffected cornea. Because we did not have a tectonic cornea at the moment of the surgery, we used a corneal-scleral rim from a previous cornea transplant to patch the huge corneal absence of tissue.

During the next 6 days, the patient received 2 more intravitreal and anterior chamber injections of amphotericin B, but no improvement was observed. The examination revealed absence of light perception and an extremely painful eye that did not respond to any analgesic drug treatment, including opioids (Fig. 3).

Based on the unfavorable outcome and the evolution to no light perception and a painful eye, an evisceration of this eye was carried out.

DISCUSSION

Surgical wound problems and corneal wound infection are rare after phacoemulsification surgery. Although there are several reports on postoperative endophthalmitis, there are very few articles on corneoscleral wound infection (4,

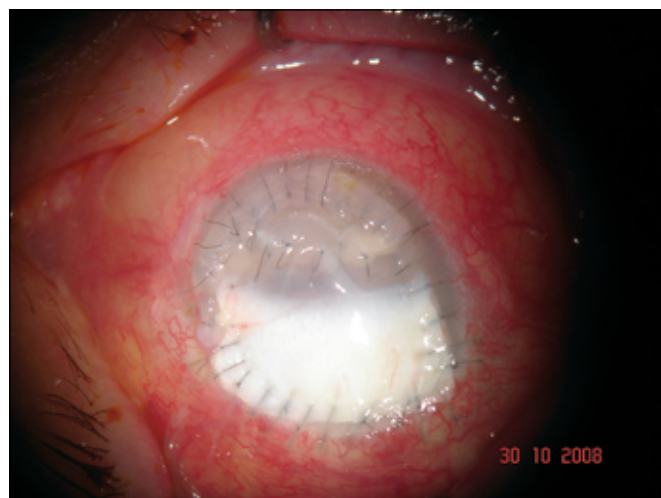


Fig. 3 - Melting recurrence a few days after keratoplasty and corneal-scleral rim interventions.

5). Fungal infection of the incision presents a therapeutic challenge because most of the available antifungal agents have a poor penetration into the corneal stroma. The use of corticosteroids after the surgical procedure may cause the infecting organisms to spread diffusely, and the fungus may gain early access to the anterior chamber and vitreous cavity (especially in aphakic and pseudophakic eyes), giving rise to endophthalmitis. Surgical treatment can be challenging because of the proximity to the limbus and the consequent high risk of recurrences from persistence of fungi on the scleral side of the wound and subsequent intraocular extension (4).

In our report, the infection was not controlled with local and systemic clinical treatment. Despite the surgical management, the patient developed recurrence of the infection, requiring evisceration of the affected eye. This is the first report of corneal wound infection by *P curvatum* after phacoemulsification. To our knowledge, 2 cases of ocular *P curvatum* infection have been reported. The first case occurred in a man who developed bilateral endogenous endophthalmitis secondary to intrapenile injections for erectile dysfunction. The final visual acuity remained limited to hand movement in both eyes, despite medical treatment and pars plana vitrectomy (6). The second was an endogenous endophthalmitis acquired through intracavernous autoinjections. In this case, the infection led to enucleation of the affected eye (7). These data corroborate our findings, showing the ominous potential of damage of this aggressive fungus to the eye structures.

No single antifungal agent has been found to be particularly effective in treating *Phialemonium* infection. In our report, the patient did not present any systemic condition such as chronic renal failure, diabetes mellitus, or other diseases that could have led to immunosuppression. No specific source of infection in this case could be identified but the use of topical corticosteroids may have contributed to the corneal invasion.

The identification of the form-species level or form-genus level is usually difficult, especially when cultures of clinical isolates are not fully sporulated or are degenerated. Important phenotypic variations, which mainly depend on the culture conditions, are shown by the isolates of this genus. *Phialemonium* spp are morphologically similar to other well-known opportunistic pathogens such as *Fusarium* spp and *Acremonium* spp. However, the susceptibilities of the isolates of these 2 genera, at least in vitro, are very different, and members of both genera display universal antifungal resistance. Due to the lack of practical data concerning the antifungal treatment of infections caused by *Phialemonium* spp, it is impossible to predict the most

adequate treatment. Our study corroborates these findings and demonstrates that the employment of molecular biology study may be necessary to diagnose this rare fungus.

The authors report no proprietary interest or financial support.

Address for correspondence:
Joao Borges Fortes Filho, MD
Department of Ophthalmology
Curso de Especialização em Oftalmologia
Hospital Banco de Olhos de Porto Alegre
Rua Eng. Walter Boehl, 285
Porto Alegre RS 91360-090, Brazil
jbfortes@cursohbo.com.br

REFERENCES

1. Heins-Vaccari EM, Machado CM, Saboya RS, et al. *Phialemonium curvatum* infection after bone marrow transplantation. *Rev Inst Med Trop Sao Paulo* 2001;43:163-166.
2. Zayit-Soudry S, Neudorfer M, Barak A, Loewenstein A, Bash E, Siegman-Igra Y. Endogenous *Phialemonium curvatum* endophthalmitis. *Am J Ophthalmol* 2005;140:755-757.
3. Weinberger M, Mahrshak I, Keller N, et al. Isolated endogenous endophthalmitis due to a sporodochial-forming *Phialemonium curvatum* acquired through intracavernous autoinjections. *Med Mycol* 2006;44:253-259.
4. Garg P, Mahesh S, Bansal AK, Gopinathan U, Rao GN. Fungal infection of sutureless self-sealing incision for cataract surgery. *Ophthalmology* 2003;110:2173-2177.
5. Kehdi EE, Watson SL, Francis IC, et al. Spectrum of clear corneal incision cataract wound infection. *J Cataract Refract Surg* 2005;31:1702-1706.
6. Strahilevitz J, Rahav G, Schroers HJ, et al. An outbreak of *Phialemonium* infective endocarditis linked to intracavernous penile injections for the treatment of impotence. *Clin Infect Dis* 2005;40:781-786.
7. Zayit-Soudry S, Neudorfer M, Barak A, Loewenstein A, Bash E, Siegman-Igra Y. Endogenous *Phialemonium curvatum* endophthalmitis. *Am J Ophthalmol* 2005;140:755-757.